

BACKGROUND

People who inject drugs (PWID) may be at an elevated risk of proteinuria and chronic kidney disease (CKD). AA (inflammatory) amyloidosis is a rare cause of proteinuria and progressive renal insufficiency in PWID, especially those with chronic or repeated skin/soft tissue infections. Case series have reported association with injection of powdered brown heroin, subcutaneous injection and HIV or viral hepatitis infection. PWID with AA amyloidosis have rapid progression to need for dialysis and high mortality after diagnosis¹⁻³. In the setting of increasing reports of severe cutaneous wounds associated with injection drug use and substances like xylazine, we sought to find out if cases of amyloidosis or proteinuric CKD have also risen.

METHODS

The authors surveyed 2800 Infectious Diseases Physicians through the Emerging Infections Network (EIN) provider-based sentinel network established by the Centers for Disease Control in the United States. A query was sent electronically 3 times in May 2023. Survey questions asked whether members who took care of PWID noted changes/increase in severity of wounds and increase diagnoses of amyloidosis or proteinuric kidney disease.

Based on these results the authors ran a query on TriNetX which is a global federated health research network providing access to electronic medical records (diagnoses, procedures, medications, laboratory values, genomic information) across large healthcare organizations (HCOs) looking for trends of diagnoses of chronic kidney disease or proteinuria among people with ICD10 diagnosis codes which are used for PWID.

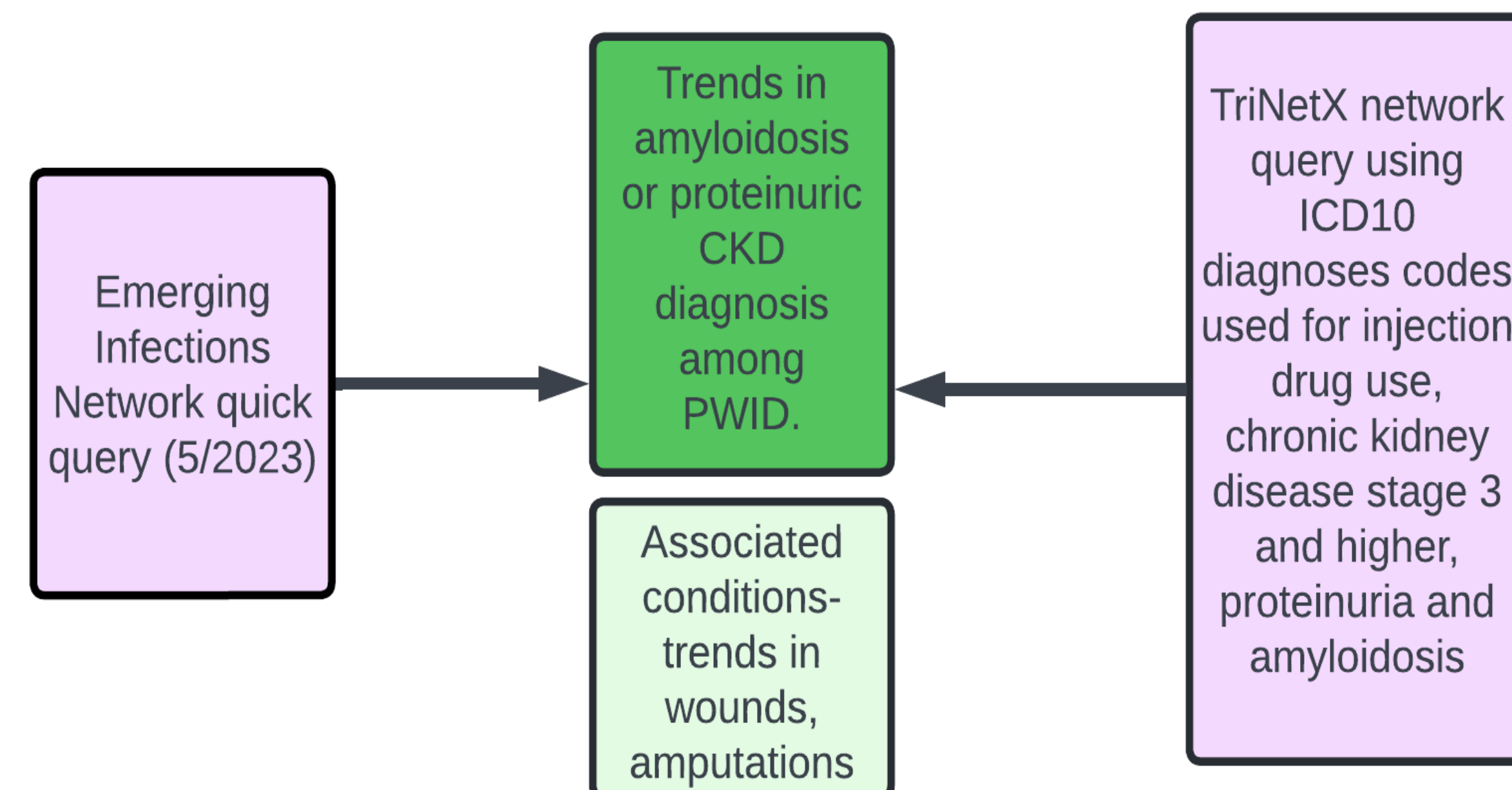
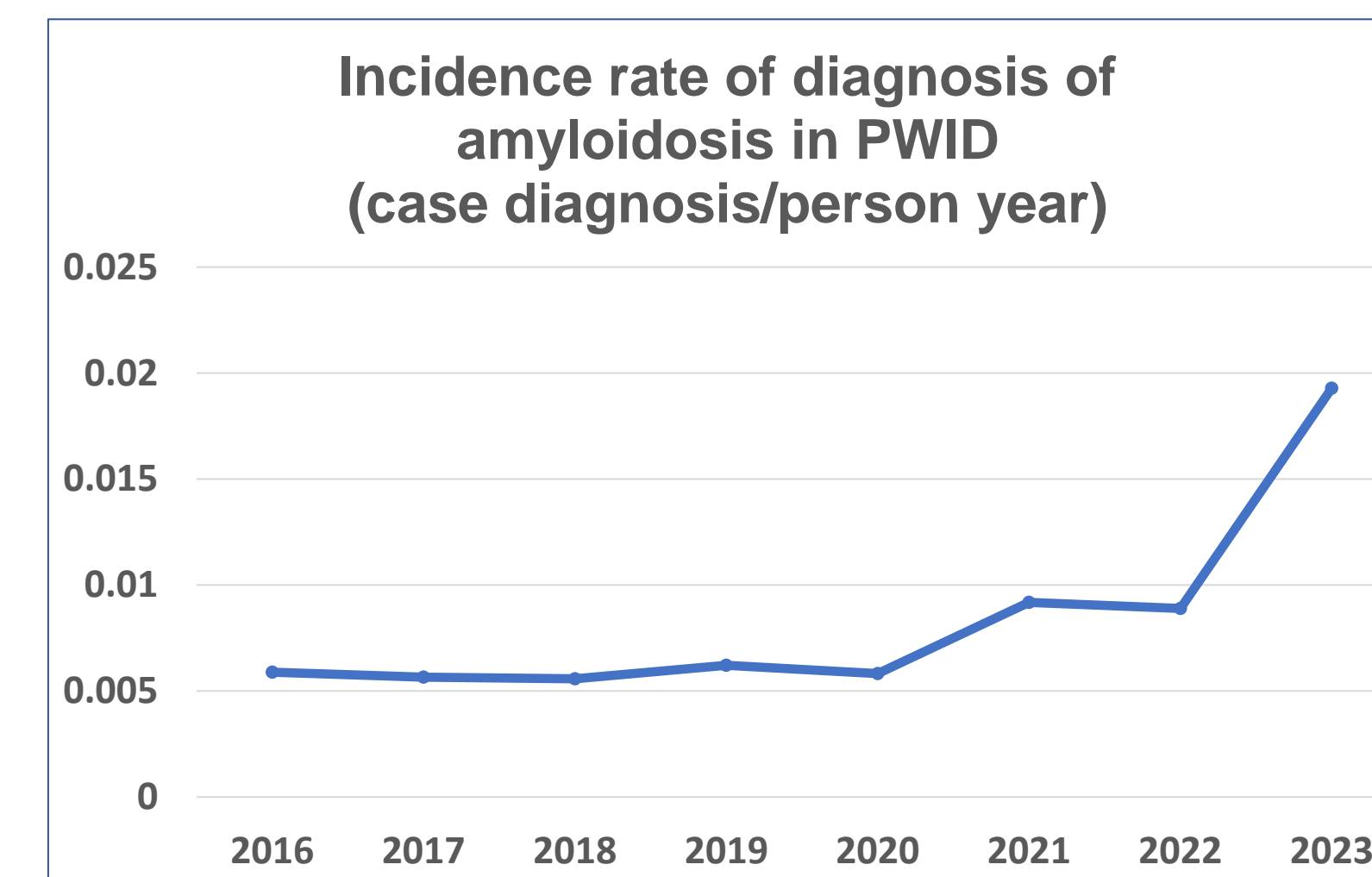
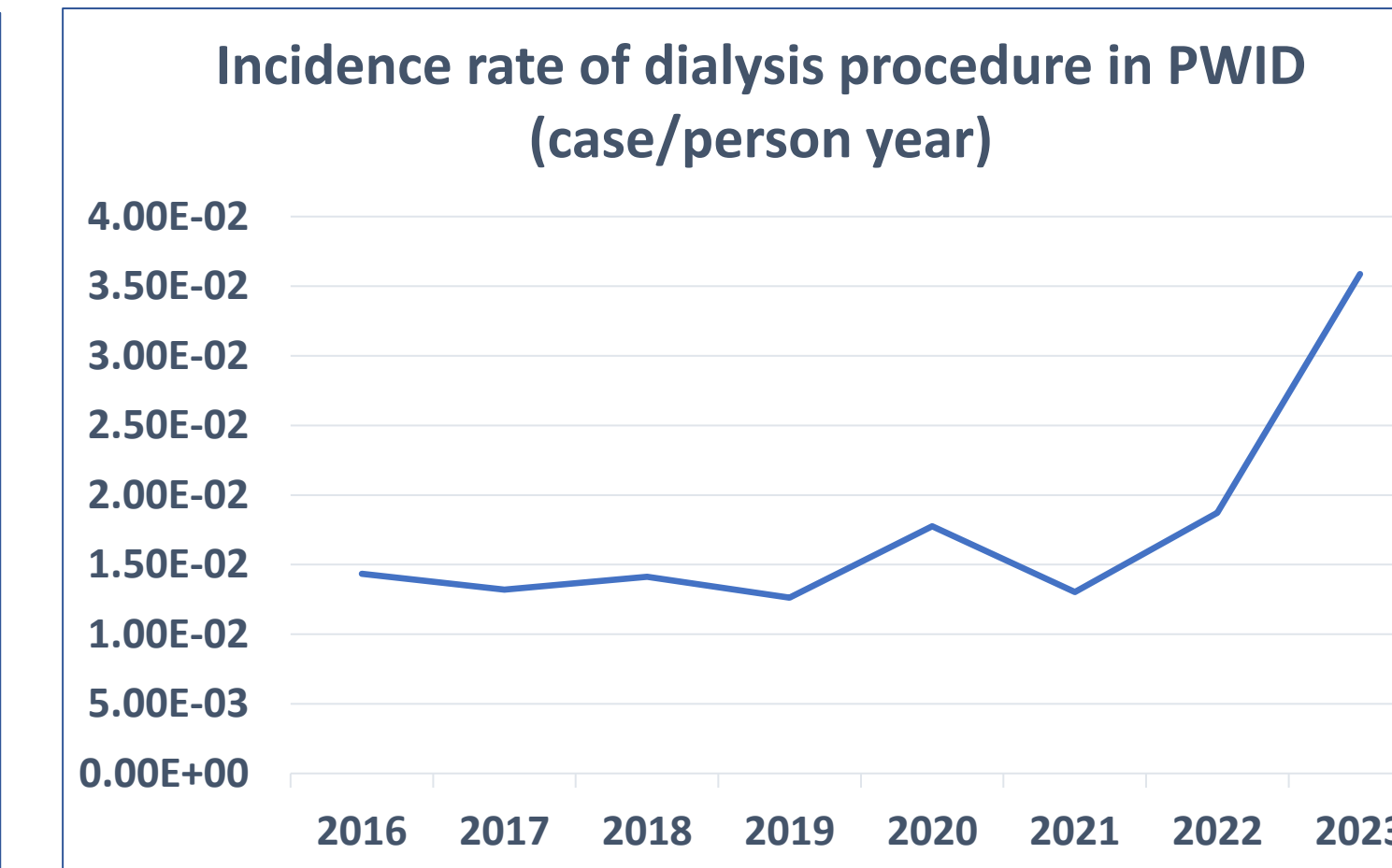
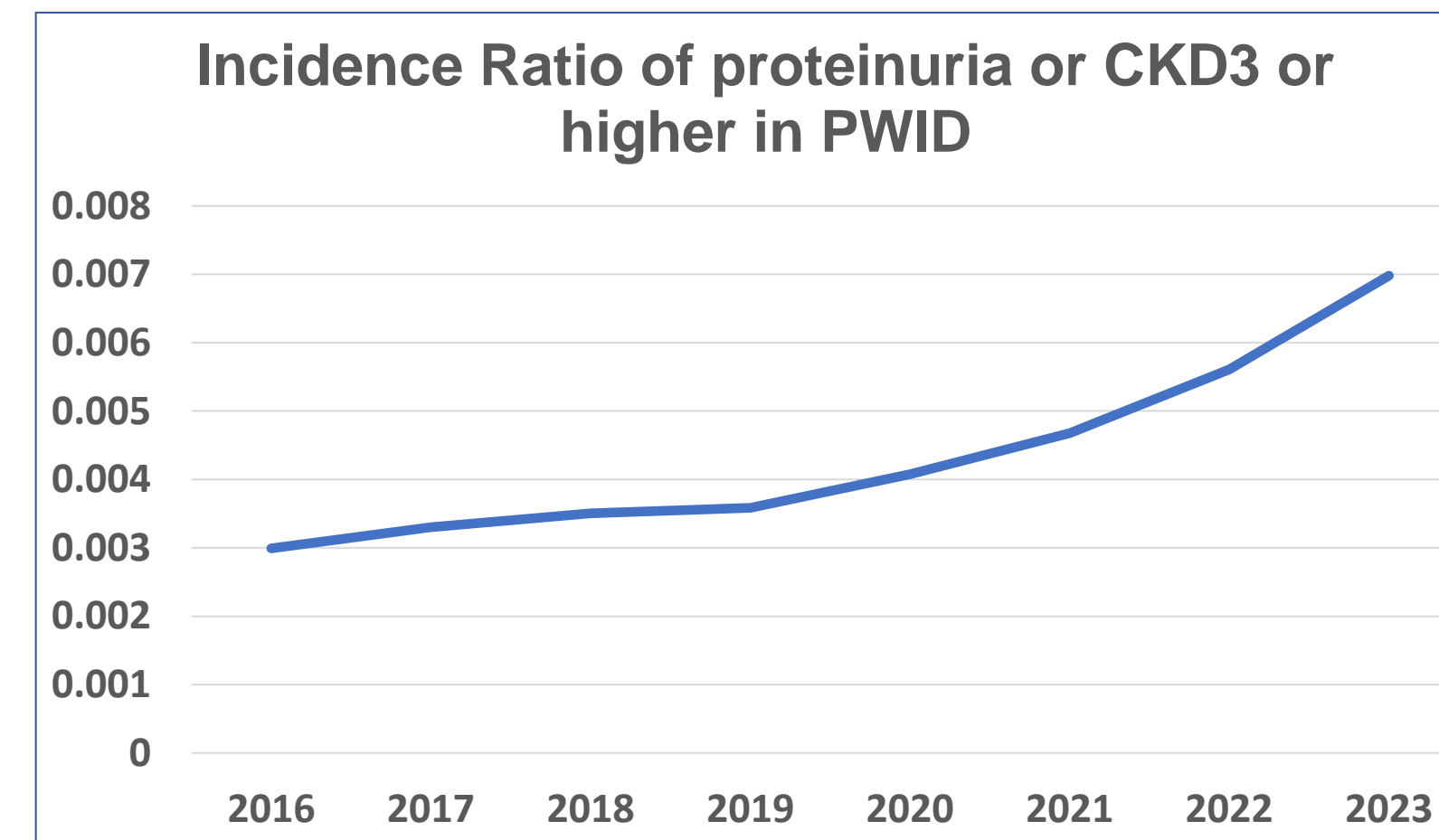


Figure 1: Study methodology

RESULTS



"We have for over 5 years been seeing AA amyloid kidney disease in PWID. It is so common here that renal isn't biopsying anymore for this & we manage empirically (after other causes have been ruled out)"

"See a lot of PWID with wounds related to xylazine, but have not seen AA amyloidosis in our population. Thank you for your message, I now will take a closer look at the urine studies for our patients"

SURVEY DATA

- 48 providers from 23 states responded to the survey.
- Responses were higher from states where AA amyloidosis in PWID has been reported (CA, WA) or where xylazine associated wounds or overdoses have been increasingly identified (PA, NY, MD).
- 36% of the respondents noted an increase in cutaneous wounds and 20% of respondents noted an increase in surgical limb amputations for wounds in PWID in the preceding 3 years.
- 27% respondents had seen proteinuric CKD and 9% had seen amyloidosis in PWID. 36% respondents had noted initiation of dialysis in PWID in the prior 3 years.

TRINETX DATA

- Analysis of EMR data from TriNetX noted that the incidence ratio of diagnoses of proteinuria or CKD3 or higher among PWID rose from 0.3% in 2016 to 0.7% in 2023 with a 2023 estimated prevalence of 3.6%. While the diagnosis of amyloidosis was rare incidence rate showed a relative rise 0.006 cases/person year in 2016 to 0.0245 cases/person year in 2023. Incidence ratios of amputation of a distal extremity rose from 0.098% in 2016 to 0.231% in 2022. Incidence rates of a dialysis procedure being done on those with PWID diagnosis also rose during this period from 0.015/person year in 2016 to 0.036/person year in 2023.

Figure 2: trends in diagnosis of proteinuric CKD, AA amyloidosis and occurrence of dialysis in PWID

CONCLUSIONS

Infectious Diseases physicians have often been at the forefront of caring for PWID due to their risk of severe and invasive infections associated with injection drug use. While physicians were unsure of whether AA amyloidosis or CKD cases are rising, they do not an increasing occurrence of severe cutaneous wounds. Nearly 10% of ID physicians have cared for PWID with an AA amyloidosis diagnosis, which is an extremely rare diagnosis and often difficult to diagnose. Indeed longitudinal EMR data seem to indicate a rising trend of proteinuric CKD and amyloidosis. A similar rising trend in major limb amputations may indicate that severe wounds related to injection drug use and their systemic consequences may also be rising.

REFERENCES

1. McGowan CR, Wright T, Nitsch D, et al. High prevalence of albuminuria amongst people who inject drugs: A cross-sectional study. *Sci Rep.* 2020;10(1).
2. Harris M, Brathwaite R, Scott J, et al. Drawing attention to a neglected injecting-related harm: a systematic review of AA amyloidosis among people who inject drugs. *Addiction.* 2018;113(10):1790-1801.
3. Sharma A, Govindan P, Toukatly M, et al. Heroin use is associated with AA-type kidney amyloidosis in the Pacific Northwest. *Clinical Journal of the American Society of Nephrology.* 2018;13(7):1030-1036.